

Revista Med

Universidad Militar Nueva Granada

revista.med@umng.edu.co

ISSN (Versión impresa): 0121-5256

ISSN (Versión en línea): 1909-7700

COLOMBIA

2006

Oscar Manrique / Rubén Peralta

SÍNDROME COMPARTIMENTAL ABDOMINAL EN PACIENTES QUEMADOS

*Revista Med*, julio, año/vol. 14, número 001

Universidad Militar Nueva Granada

Bogotá, Colombia

pp. 40-47

Red de Revistas Científicas de América Latina y el Caribe, España y Portugal

---

Universidad Autónoma del Estado de México

<http://redalyc.uaemex.mx>



## SÍNDROME COMPARTIMENTAL ABDOMINAL EN PACIENTES QUEMADOS

OSCAR MANRIQUE<sup>1\*</sup>. AND RUBÉN PERALTA<sup>1</sup>

### Resumen

El síndrome compartimental abdominal (SCA) es una condición común que se produce en una gran variedad de escenarios clínicos, siendo reportado en diferentes series de trauma entre el 6 y 35% de los casos. Hay muchas etiologías que conllevan a un aumento de la presión intra-abdominal incluyendo las quemaduras masivas. Cuando se produce una alta presión intra-abdominal y no se corrige a tiempo, se da paso a una entidad descrita como síndrome compartimental abdominal, con subsiguiente falla multisistémica y muerte. El propósito de esta revisión, es describir la fisiopatología del SCA en pacientes quemados, reconocer y diagnosticar tempranamente del aumento de la presión intra-abdominal, también conocido como hipertensión abdominal, y describir los actuales métodos diagnósticos y el tratamiento, de tal manera que se pueda prevenir la falla multi-orgánica producida en esta entidad.

**Palabras clave:** pacientes quemados, trauma cerrado.

## ABDOMINAL COMPARTMENT SYNDROME IN BURN PATIENTS

### Abstract

Abdominal compartment syndrome (ACS) is a very common condition that occurs in a wide variety of clinical scenarios, ranging in different trauma series from 6% to 35%. There are many etiologies which lead to an increase intrabdominal pressure including massive burns. When high intrabdominal pressure develops and is not corrected in an early course, will lead to a well known scenario called abdominal compartment syndrome with subsequently multiple organ failure end death. The purpose of this review is to describe the pathophysiology of ACS in burn patients, the importance of early recognition and diagnosis of intrabdominal hypertension (IAH) and to describe some of the current diagnosis and treatment methods to prevent further organ failure.

**Key words:** burned patients, blunt trauma.

### Introduction

Abdominal compartment syndrome (ACS) is a very common condition that occurs in a wide variety of clinical scenarios. Ascites, blunt or penetrating abdominal trauma, mechanical bowel obstruction,

liver transplantation, packing for uncontrollable intrabdominal bleeding, and large burns are some of them<sup>1-6</sup>. An abdominal compartment syndrome occurs when a less compliant, more rigid tissue surrounds an expandable tissue (Figure 1). This acute increased intrabdominal pressure (IAP), if not

---

<sup>1</sup> Massachusetts General Hospital. Harvard Medical School.

\* Dirección electrónica para correspondencia: [oscarj.manrique@gmail.com](mailto:oscarj.manrique@gmail.com)

Dirección postal: Massachusetts General Hospital, Harvard Medical School. 55 Fruit Streer, Boston. Massachusetts 02114 USA.

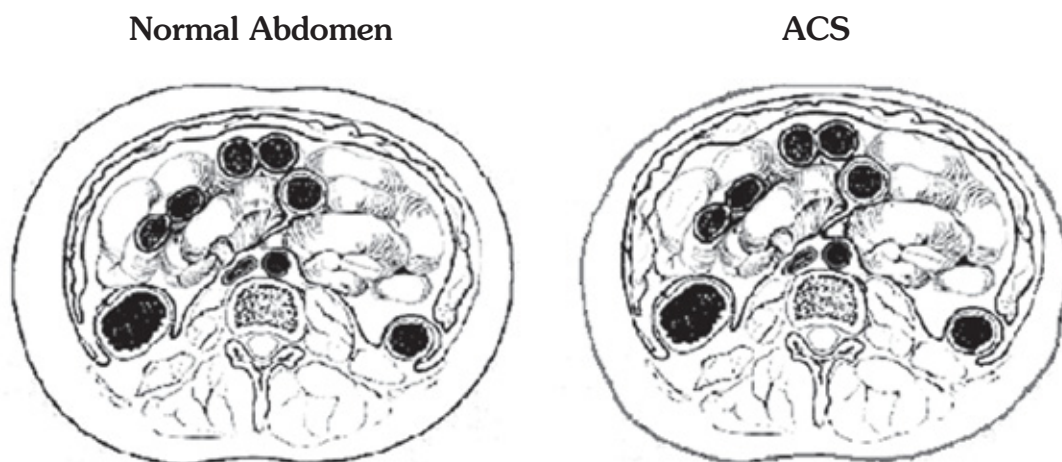
Recibido: Marzo 1 de 2005. Aceptado: Abril 8 de 2006.

corrected in an early course, will produce intrabdominal hypertension (IAH) and ACS leading to organ failure and death. Early recognition and treatment of this condition is important to decrease morbidity and mortality caused by high IAP. Persistent increased IAP will involve many of the organ systems, being more frequently affected the respiratory, cardiovascular and renal systems<sup>7</sup>.

Although many cases have been reported as the cause of ACS, this entity has not been widely described for burn patients. The exact incidence of ACS has not yet been estimated, however some trauma series have reported an incidence between 5.5% and 35%<sup>8,9</sup>. Other reports concluded that the incidence of ACS correlates with the burn size and burn depth<sup>6,10</sup>. Tension of the abdominal and thoracic wall secondary to the full-thickness burn eschar, burn sepsis, bowel edema and massive fluid resuscitation are some of the predisposing factors to develop IAH<sup>11</sup>. The level at which IAH is converted to ACS is controversial. However, oliguria, hypercapnia, and high inspiratory pressures during mechanical ventilation are considered diagnostic parameters for ACS<sup>2</sup>. The purpose of our review is to describe the pathophysiology of ACS in burn patients, the importance of early diagnosis of IAH for burn patients, and to describe some of the current diagnosis and treatment methods.

## Historical perspective

Since the last half of the nineteenth century reports have documented the presentation of ACS<sup>12</sup>. One of the first reports of ACS was done by Heinrich in 1890, who demonstrated in a animal model that the artificial increase of IAP will lead to death secondary to respiratory failure<sup>12</sup>. In addition, Emerson<sup>13</sup> also described the pulmonary dysfunction produced with high IAP. In 1913, Wendt was the first one to describe the association between IAH and renal dysfunction<sup>14,15</sup>. One decade later, Thorington and Schmidt<sup>16</sup> reported the effects of IAH in the renal system. In an animal model they showed that an acute increase of IAP between 15 to 30 mmHg could lead to oliguria, and any pressure above 30 mmHg could progress to anuria and death. In 1931, Overholt<sup>17</sup> was the first person to measure the intrabdominal pressure using a fenestrated catheter and to demonstrate that this effect was due to hydrostatic pressure of the viscera. In 1980, Kron<sup>18</sup> was the first to introduce the term ACS and to describe the first case of ACS secondary to aortic aneurysm repair. In the last decade, important contributions have been made in terms of early diagnosis and treatment for this condition. However, just only few articles have described the ACS in burned patients.



**FIGURE 1.** Left: Drawing of a normal abdomen. Right: ACS. Decreased anterior abdominal wall with bowel edema and decreased intraperitoneal space.

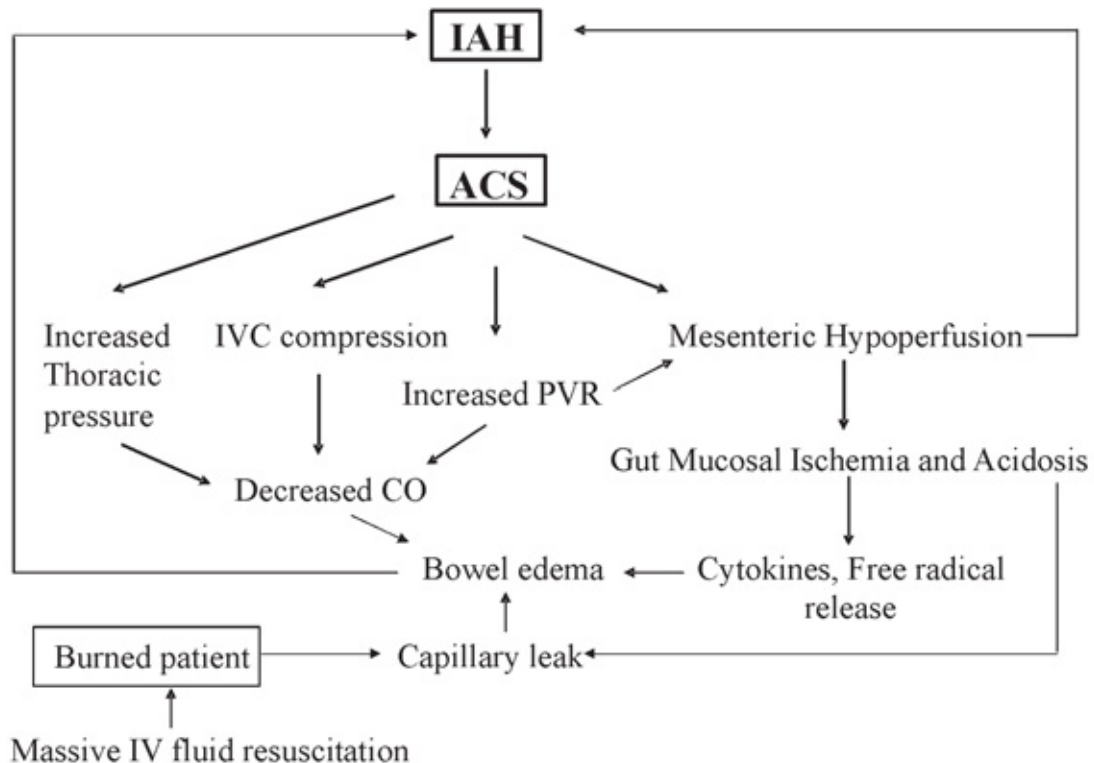
## Pathophysiology

In shock states, blood shunts away from peripheral tissues like the skin or muscle to supply important organs like the brain, heart and kidneys. This redistribution is mediated by the sympathetic nervous system, which produces vasoconstriction and decreased blood flow to the peripheral tissues. When blood shunts away from the gut, this effect will generate cellular hypoxia in the intestinal epithelium. Prolonged hypoxia will obligate the cells to suffer an acidotic environment releasing inflammatory cytokines, oxygen free radicals, and decreased production of adenosine triphosphate (ATP)<sup>19</sup>. The release of these pro-inflammatory products will increase capillary permeability and tissue edema. In burn patients, also the addition of aggressive fluid resuscitation will generate a reperfusion syndrome, releasing more toxic substances affecting even more the cell membranes. When the cell membrane is damaged, the main pump of the cell

(Na/K ATPase) is destroyed, producing cell edema and abnormal fluid cell compensation. Ischemia can also impact closure of the abdominal wall after a prolonged laparotomy in that decreased perfusion of the wound edges, can compromise healing of the wound. Prolonged increased intrabdominal pressure will disturb many organ systems, most commonly affecting the central nervous system (CNS), cardiac, pulmonary and renal systems. This will generate a vicious cycle leading to organ failure and death (Figure 2).

## Central Nervous System

A major concern with ACS is secondary increased intra-cranial pressure (ICP) and reduced cerebral perfusion pressure (CPP)<sup>20-22</sup>. Animal models of ACS have demonstrated that the increase in ICP and reduction in CPP are independent of changes in the pulmonary or cardiovascular functions.



**FIGURE 2.** Physiopathology cycle of ACS in burn patients.

However, they appear to be the direct result of elevated intrathoracic and central venous pressures leading to impairment of the cerebral venous outflow<sup>21,22</sup>. The precise mechanisms in which increased IAP affects ICP and CPP are not yet elucidated. Some other theories suggest that the central venous pressure (CVP) due to elevated IAP may interfere with cerebral venous drainage, increase the size of the intracranial vascular bed, and raise ICP<sup>23</sup>. Reports have demonstrated that decompression of the abdominal cavity reverses this CNS compromise<sup>1,24</sup>, arguing that this effect is mainly mechanical secondary to diaphragmatic elevation, reduced chest wall compliance, and increased CVP<sup>25</sup>. Although it is questionable whether this increase in ICP is associated with decreased CPP in normal patients<sup>26</sup>. Many reports have an association between increased ICP and ACS, although no report has shown an association in burn patients with ACS and adverse effects on ICP or CPP.

### Cardiovascular System

The most common effect of ACS is decreased cardiac output (CO)<sup>27-33</sup>. Kashtan et al<sup>32</sup> demonstrated that hypovolemic animals had severe decrease in CO with increased IAP, normovolemic animals had minimal decrease, and hypervolemic animals had increased CO. The main mechanism affecting CO is venous return. The increased IAP compresses the inferior vena cava (IVC) thus decreasing CO<sup>34,35</sup>. The maximal resistance to caval flow occurs at the suprahepatic, subdiaphragmatic IVC, where the high-pressure zone of the abdomen meets the lower pressure of the thorax<sup>36</sup>. Besides the compression of the IVC, increased vascular resistance and changes in the position of the heart due to diaphragm elevation have been proposed as other main mechanisms affecting CO<sup>35</sup>. This elevation of systemic vascular resistance is secondary to the reduction of CO and direct arteriolar compression within the abdomen<sup>37</sup>. In addition, other reports showed that increased intrathoracic pressure decreases the ventricular end-diastolic volume<sup>38,39</sup>. Many burn patients receive massive fluid resuscitation, creating a hypervolemic state, which protects the patient against any reduction in CO like demonstrated by Kashtan<sup>32</sup>. However other circumstances like massive capillary leaking,

generation of a third space and compensation of the fluid already lost by the burn itself will tend to decrease the intravascular volume.

### Respiratory System

The main effect of IAP on the respiratory system is also mainly mechanical. In a swine model, Riddings et al. showed the relationship between increased IAP, decreased PO<sub>2</sub> and increased PCO<sub>2</sub><sup>37</sup>. Other reports in animal models showed that when IAP was between 20 and 25 mmHg, pressure would force the diaphragm to be pushed against the chest cavity<sup>39</sup>. The incursion of the diaphragm will compress the lungs, increase the intrathoracic pressure, decrease lung compliance and decrease tidal volume. All these effects will lead to alveolar hypoventilation with increased dead space and hypercarbia. Lung compression will predispose to atelectasis, areas of ventilation-perfusion mismatch, and hypoxemia, increasing the incidence of nosocomial pneumonia. In addition, many burn patients also have airway compromise secondary to trauma or inhalation injury. A burned airway will produce a decrease compliance of the small airways, edema, capillary leakage and airway plugging. The common presentation of pulmonary compromise secondary to ACS will be high peak inspiratory pressures and very low respiratory system compliance. Chest imaging can help to localize the areas of major compromise. Positive end-expiratory pressure (PEEP) is required to maintain adequate oxygenation and decrease the areas of ventilation-perfusion mismatch<sup>44</sup>.

### Renal System

Renal derangements in ACS manifest most commonly as oliguria. If pressures are high and prolonged enough complete anuria can occur<sup>30,40,45,46</sup>. Renal dysfunction is characterized by oliguria, anuria and prerenal azotemia unresponsive to volume expansion. The cause of the decrease in urine output is multifactorial. The first experiments to understand the physiopathology of ACS in the renal system were conducted by Harman et al.<sup>30</sup>. They noted a marked decrease in the glomerular filtration rate (GFR) and CO after the IAP was artificially increased in their animal models. The decreased GFR was

attributed to a direct compression to the renal parenchyma and blood supply. In addition, increased vascular resistance with changes in intrarenal regional blood flow and increased tubular sodium-water retention, will contribute to this effect<sup>30,46</sup>. Ureteral occlusion with postrenal azotemia can be eliminated as an important causal factor in ACS because placement of ureteral stents did not improve renal function<sup>30</sup>.

For burn patients we have to add other important factors that are associated with renal compromise. The lack of adequate intravascular flow is secondary to fluid loss and the generation of third space compartments. This volume reduction associated with the release of high amounts of myoglobin and high molecular weight products from the muscle will directly affect the glomerular filtration system decreasing the GFR. Decompression and reduction of the IAP in addition to high volume replacement will reverse this renal compromise<sup>38,47-49</sup>.

### Abdominal Visceral and Wall Abnormalities

During ACS, most of the intrabdominal viscera blood flow is reduced<sup>50,51</sup>. Diebel et al. demonstrated that even with an IAP of 10 mmHg, organs like the liver begin to decrease their blood supply. An IAP above 20 mmHg, will reduce mesenteric and intestinal mucosa flow, impairing intestinal perfusion at the mucosal and submucosal levels, leading to reduction in tissue oxygen tension, anaerobic cell metabolism, acidosis, bacterial translocation and free radical generation<sup>52,53</sup>. Some reports have suggested that prolonged bowel ischemia is associated with an increased incidence of multiple organ failure, sepsis, and increased mortality<sup>54</sup>. Further investigations have shown that a prolonged increased IAP may lead to intestinal infarction, which most commonly presents in the ileum and right colon<sup>39</sup>.

Diebel et al.<sup>55</sup> described how high IAP reduce abdominal wall blood flow. In burn patients there are many factors affecting abdominal wall perfusion. Prolonged IAH will create a compressive effect over the abdominal wall leading to edema and even ischemia. In addition to the lack of adequate peripheral perfusion, the lost tissue

secondary to the burn will further complicate healing. This will decrease abdominal wall compliance and increase pressures within the abdominal cavity, exposing abdominal organs to prolonged high pressures.

### Diagnosis

Based on the patient's clinical scenario and physical exam, the diagnosis of ACS is generally straightforward. Our experience has shown that most of the patients present with a tense abdomen, although ACS can occur with a normal abdominal examination. Patients at risk for developing ACS are those who underwent prolonged intrabdominal or retroperitoneal surgery and patients who have required vigorous resuscitation for shock or extensive burns. However, those patients who are at highest risk include postoperative laparotomy due to abdominal trauma and abdominal packing for damage control. In addition, coagulopathies, cirrhosis, idiopathic thrombocytopenia purpura or profound hypothermia can further elevate the risk for ACS<sup>56,57</sup>. The most common physical findings in patients with ACS are tensely distended abdomen, progressive oliguria despite adequate CO or volume replacement, and/or hypoxia with increased airway pressures<sup>41</sup>. Besides physical findings, more objective methods are necessary to diagnose the increased IAP. The IAP can be measured by direct or indirect methods. The direct methods are rarely used because of the invasive nature of the procedure that makes it impractical in the ICU setting. The most common methods used to measure IAP are the indirect methods. Measuring the bladder pressure is very accurate, easy and highly cost-effective.

Kron et al<sup>18</sup> described the first technique for measuring IAP in patients with ACS. He explained that the bladder acts as a passive reservoir at volumes less than 100 mL, and that it is capable of transmitting IAP without imparting any additional pressure from its own musculature. Contraindications like neurogenic or contracted bladder are very uncommon in the clinical practice<sup>58</sup>. Other indirect methods less commonly used are placement of a central venous catheter in the IVC<sup>59,60</sup> and measurement of intragastric pressure via a nasogastric tube<sup>61</sup>. There is not an exact IAP at which patients manifest clinical signs of ACS. Therefore the diag-

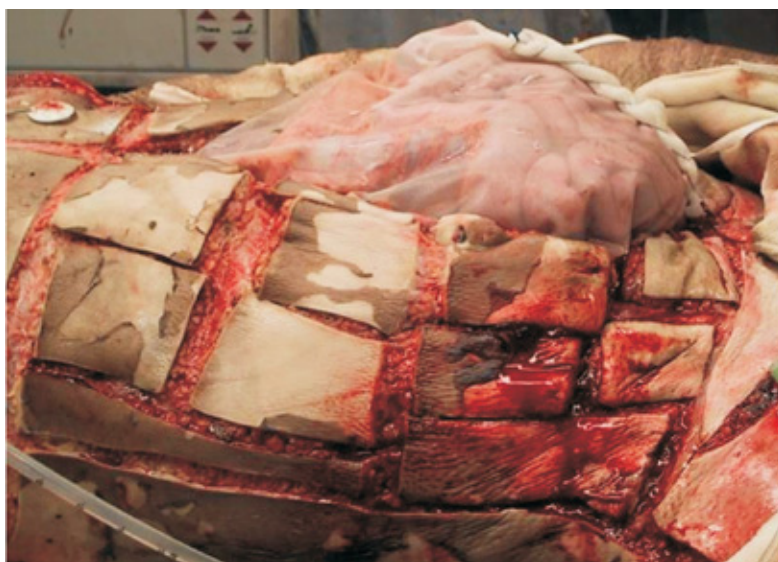nosis depends on the patient physiologic responses to increased IAP.

## Treatment

The treatment depends on the clinical presentation, burn total body surface area (TBSA) and level of IAP. However, the main goal should always focus on prevention strategies. Early detection and treatment with noninvasive measures is important, because many of the complications already described occur long before the syndrome is clinically obvious. Any patient with ACS, especially those with large burns should be aggressively fluid resuscitated, while monitoring hemodynamics, physical exam, and urine output<sup>40,62,63</sup>. Greenhalgh found that the development of IAH was correlated with the percentage of burnt body surface area, percentage of full thickness burnt and sepsis<sup>6</sup>. Ivy documented that IAH developed in patients with more than 20% TBSA and ACS with more than 70% of TBSA in primarily full thickness burns<sup>64</sup>.

Some authors have suggested that when TBSA is lower than 80% and IAP is between 15-20 mmHg an intrabdominal percutaneous drainage catheter should be inserted<sup>65</sup>. However, when the patient has a burn area with more than 80% of TBSA and

inhalation injury, this technique is more likely to fail and may require laparotomy for decompression. Burch<sup>41</sup>, has reported a grading scale for the treatment and management of patients with ACS. Grade I is considered when IAP is between 10-15 mmHg; conservative therapy is appropriate at this point. With IAP between 15 and 25 mmHg, the patient is considered grade II, and treatment is still generally conservative. These conservative measurements include flushing the bladder catheter to ensure patency, nasogastric tube decompression, bowel care, and escharotomies for any existing circumferential abdominal or thoracic wound<sup>66</sup>. Additional measures like sedation and pharmacological paralysis can be very effective reducing IAP. Patients with grade III IAP (25-35 mmHg), require abdominal decompression, although signs and symptoms may develop insidiously. All patients in grade IV (>35 mmHg) require abdominal decompression via laparotomy (Figure 3). The most cost effective method to prevent ACS is the "Bogotá bag", which is a sterilized 3 liter urologic irrigation bag sutured to the patients fascia<sup>56</sup>. Hobson et al<sup>66</sup>, reported that treatment with abdominal decompression improved survival in 40% of burn patients with ACS. They recommend initial bladder pressure monitoring and laparotomy in any patient who develops an IAP higher than 30 mmHg. After the acute episode resolves, the laparotomy should be closed as soon as possible.



**FIGURE 3.** Burn patient who developed ACS and treated with midline laparotomy and covered with silo. Courtesy from Robert L. Sheridan, MD.

However, many argue that a laparotomy in burn patients will bring additional morbidity, making decompression a higher risk than conservative therapy. When most of the anterior abdominal wall is burnt, a midline incision can predispose to intrabdominal infections<sup>67</sup>. Corcos et al., proposed percutaneous drainage of peritoneal fluid in early stages of IAH<sup>67</sup>.

## Recommendations

Clinical signs will lead us to diagnose ACS. However, more accurate methods are necessary to find initial changes in IAP. No matter the clinical picture of the patient, the main standard of treatment is to prevent the increase of IAP for patients with large burn TBSA. Based on our clinical experience, any patient with a TBSA of more than 20%, bladder pressure should always be monitored. For patients with a TBSA of less than 80% and IAP of less than 25 mmHg, a conservative therapy should be done. For patients with the same or even less TBSA but an IAP above 25 mmHg percutaneous drainage should be performed. This less invasive technique is appropriate to reduce significant complications secondary to the burn itself. However, patients with IAP higher than 30 mmHg will require obligatory laparotomy, covering the bowels with silastic. However, after laparotomy, these patients should be closely monitored for clinical improvement so the laparotomy could be closed as soon as possible to decrease further complications.

## References

1. Bloomfield, G.L. Treatment of increasing intracranial pressure secondary to the acute abdominal compartment syndrome in a patient with combined abdominal and head trauma. *J Trauma*. 1995; 39(6):1168-70.
2. Ivatury, R.R. Intra-abdominal hypertension and the abdominal compartment syndrome. *Surg Clin North Am*. 1997; 77(4): 783-800.
3. Ivatury, R.R. Intra-abdominal hypertension after life-threatening penetrating abdominal trauma: prophylaxis, incidence, and clinical relevance to gastric mucosal pH and abdominal compartment syndrome. *J. Trauma*. 1998. 44(6): 1016-23.
4. Eddy, V. C. Nunn, J.A. Morris, Jr. Abdominal compartment syndrome. The Nashville experience. *Surg Clin North Am* 1997; 77(4): 801-12.
5. Savino, J.A. Manipulation of ascitic fluid pressure in cirrhotics to optimize hemodynamic and renal function. *Ann Surg* 1988; 208(4): 504-11.
6. Greenhalgh, D.G, Warden, G. The importance of intra-abdominal pressure measurements in burned children. *J Trauma*. 1994; 36(5): 685-90.
7. Fietsam, R., Jr. Intra-abdominal compartment syndrome as a complication of ruptured abdominal aortic aneurysm repair. *Am Surg*. 1989; 55(6): 396-402.
8. Mayberry, J.C. Prevention of abdominal compartment syndrome by absorbable mesh prosthesis closure. *Arch Surg*. 1997; 132(9): 957-61.
9. Ertel, W. Incidence and clinical pattern of the abdominal compartment syndrome after "damage-control" laparotomy in 311 patients with severe abdominal and/or pelvic trauma. *Crit Care Med*. 2000; 28(6): 1747-53.
10. Ivy, M.E. Intra-abdominal hypertension and abdominal compartment syndrome in burn patients. *J Trauma*, 2000; 49(3): 387-91.
11. Tsoutsos, D. Early escharotomy as a measure to reduce intraabdominal hypertension in full-thickness burns of the thoracic and abdominal area. *World J Surg*. 2003; 27(12): 1323-8.
12. Coombs, H. The mechanisms of the regulation of intra-abdominal pressure. *Am J of Physiology*. 1920; 61: 159-163.
13. Emerson, H. Intra-abdominal pressures. *Arch Intern Med*. 1911; 7: 754-784.
14. Abeshouse, B. Renal decapsulation: a review of the literature and a report of ten cases. *J Urol*. 1945; 53: 27-32.
15. SE Bradley, G.B. The effect of increased intra-abdominal pressure on renal function. *J Clin Invest*. 1947; 26: 1010-1015.
16. Thorington JM, S.C. A study of urinary output and blood pressure changes resulting in experimental ascites. *Am J Med Sci*. 1923; 165 880-886.
17. Overholt, R. Intraperitoneal pressure. *Archives of Surgery*. 1931; 22: 691-703.
18. Kron, I.L., P.K. Harman, and S.P. Nolan. The measurement of intra-abdominal pressure as a criterion for abdominal re-exploration. *Ann Surg*. 1984; 199(1): 28-30.
19. Walker, J. and L.M. Criddle. Pathophysiology and management of abdominal compartment syndrome. *Am J Crit Care*. 2003; 12(4): 367-71.
20. Josephs, L.G., et al. Diagnostic laparoscopy increases intracranial pressure. *J Trauma*. 1994; 36(6): 815-8.
21. Bloomfield, G.L., et al. A proposed relationship between increased intra-abdominal, intrathoracic, and intracranial pressure. *Crit Care Med*. 1997; 25(3): 496-503.
22. Bloomfield, G.L., et al. Effects of increased intra-abdominal pressure upon intracranial and cerebral perfusion pressure before and after volume expansion. *J Trauma*. 1996; 40(6): 936-41.
23. Rosenthal, R.J., et al. Intracranial pressure. Effects of pneumoperitoneum in a large-animal model. *Surg Endosc*. 1997; 11(4): 376-80.
24. Irgau, I., Y. Koyfman, Tikellis, J. Elective intraoperative intracranial pressure monitoring during laparoscopic cholecystectomy. *Arch Surg*. 1995; 130(9): 1011-3.
25. Peralta, R, Hojman, H. Abdominal compartment syndrome. *Int Anesthesiol Clin*. 2001; 39(1): 75-94.
26. Kirkinen, P., et al. Intracranial blood flow during laparoscopic hysterectomy. *Acta Obstet. Gynecol. Scand*. 1995; 74(1): 71-4.
27. Burchard, K.W., et al. Positive end expiratory pressure with increased intra-abdominal pressure. *Surg Gynecol Obstet*. 1985; 161(4): 313-8.

28. Caldwell, C, Ricotta, J. Changes in visceral blood flow with elevated intraabdominal pressure. *J Surg Res.* 1987; 43(1): 14-20.
29. Diamant, M., J.L. Benumof, Saidman, L. Hemodynamics of increased intra-abdominal pressure: Interaction with hypovolemia and halothane anesthesia. *Anesthesiology.* 1978; 48(1): 23-7.
30. Harman, P.K., et al. Elevated intra-abdominal pressure and renal function. *Ann Surg.* 1982; 196(5): 594-7.
31. Ivankovich, A.D., et al. Cardiovascular effects of intraperitoneal insufflation with carbon dioxide and nitrous oxide in the dog. *Anesthesiology.* 1975; 42(3): 281-7.
32. Kashtan, J., et al. Hemodynamic effect of increased abdominal pressure. *J Surg Res.* 1981; 30(3): 249-55.
33. Lynch, F.P., et al. Cardiovascular effects of increased intra-abdominal pressure in newborn piglets. *J Pediatr Surg.* 1974; 9(5): 621-6.
34. Doppman, J., et al. Mechanism of obstruction of the infradiaphragmatic portion of the inferior vena cava in the presence of increased intra-abdominal pressure. *Invest Radiol.* 1966; 1(1): 37-53.
35. Rubinson, R.M., et al. Inferior vena caval obstruction from increased intra-abdominal pressure. Experimental hemodynamic and angiographic observations. *Arch Surg.* 1967; 94(6): 766-70.
36. Takata, M., R.A. Wise, Robotham, J. Effects of abdominal pressure on venous return: abdominal vascular zone conditions. *J Appl Physiol.* 1990; 69(6): 1961-72.
37. Ridings, P.C., et al. Cardiopulmonary effects of raised intra-abdominal pressure before and after intravascular volume expansion. *J Trauma.* 1995; 39(6): 1071-5.
38. Shelly, M.P., et al. Haemodynamic effects following surgical release of increased intra-abdominal pressure. *Br J Anaesth.* 1987; 59(6): 800-5.
39. Saggi, B.H., et al. Abdominal compartment syndrome. *J Trauma.* 1998; 45(3): 597-609.
40. Cullen, D.J., et al. Cardiovascular, pulmonary, and renal effects of massively increased intra-abdominal pressure in critically ill patients. *Crit Care Med.* 1989; 17(2): 118-21.
41. Burch, J.M., et al. The abdominal compartment syndrome. *Surg Clin North Am.* 1996; 76(4): 833-42.
42. Burchard, K.W. Cardiovascular, pulmonary, and renal effects of massively increased intra-abdominal pressure in critically ill patients. *Crit Care Med.* 1990; 18(1): 120.
43. Nathens, A.B., F.D. Brenneman, Boulanger, B. The abdominal compartment syndrome. *Can J Surg.* 1997; 40(4): 254-8.
44. Simon, R.J., et al. Hemorrhage lowers the threshold for intra-abdominal hypertension-induced pulmonary dysfunction. *J Trauma.* 1997; 42(3): 398-403.
45. Celoria, G., et al. Oliguria from high intra-abdominal pressure secondary to ovarian mass. *Crit Care Med.* 1987; 15(1): 78-9.
46. Kirsch, A.J., et al. Renal effects of CO<sub>2</sub> insufflation: oliguria and acute renal dysfunction in a rat pneumoperitoneum model. *Urology* 1994; 43(4): 453-9.
47. Jacques, T, Lee, R. Improvement of renal function after relief of raised intra-abdominal pressure due to traumatic retroperitoneal haematoma. *Anaesth Intensive Care.* 1988; 16(4): 478-82.
48. Smith, J, Merrell, R, Raffin, T. Reversal of postoperative anuria by decompressive celiotomy. *Arch Intern Med.* 1985; 145(3): 553-4.
49. Richards, W.O., et al. Acute renal failure associated with increased intra-abdominal pressure. *Ann Surg.* 1983; 197(2): 183-7.
50. Diebel, L.N, Dulchavsky, S, Wilson, R. Effect of increased intra-abdominal pressure on mesenteric arterial and intestinal mucosal blood flow. *J Trauma.* 1992; 33(1): 45-8.
51. Diebel, L.N., et al. Effect of increased intra-abdominal pressure on hepatic arterial, portal venous, and hepatic microcirculatory blood flow. *J Trauma.* 1992; 33(2): 279-82.
52. Sugrue, M., et al. Intraabdominal pressure and gastric intramucosal pH: is there an association? *World J Surg.* 1996; 20(8): 988-91.
53. Eleftheriadis, E., et al. Gut ischemia, oxidative stress, and bacterial translocation in elevated abdominal pressure in rats. *World J Surg.* 1996; 20(1): 11-6.
54. Marshall, J.C., et al. The microbiology of multiple organ failure. The proximal gastrointestinal tract as an occult reservoir of pathogens. *Arch Surg.* 1988; 123(3): 309-15.
55. Diebel, L, Saxe, J, Dulchavsky, S. Effect of intra-abdominal pressure on abdominal wall blood flow. *Am Surg.* 1992; 58(9): 573-5.
56. Burch, J, Richardson R.J. Abbreviated laparotomy and planned reoperation for critically injured patients. *Ann Surg.* 1991; 215: 476-484.
57. Morris, J.A., Jr., et al. The staged celiotomy for trauma. Issues in unpacking and reconstruction. *Ann Surg.* 1993; 217(5): 576-84.
58. Schein, M., et al. The abdominal compartment syndrome: the physiological and clinical consequences of elevated intra-abdominal pressure. *J Am Coll Surg.* 1995; 180(6): 745-53.
59. Richardson, J.D, Trinkle, J. Hemodynamic and respiratory alterations with increased intra-abdominal pressure. *J. Surg. Res.* 1976; 20(5): 401-4.
60. Iwase, K., et al. Intra-abdominal venous pressure during laparoscopic cholecystectomy. *HPB Surg.* 1994; 8(1): 13-7.
61. Sugrue, M., et al. Intra-abdominal pressure measurement using a modified nasogastric tube: description and validation of a new technique. *Intensive Care Med.* 1994; 20(8): 588-90.
62. Durham, R., et al. Right ventricular end-diastolic volume as a measure of preload. *J Trauma.* 1995; 39(2): 218-23.
63. Cheatham, M.L., et al. Right ventricular end-diastolic volume index as a predictor of preload status in patients on positive end-expiratory pressure. *Crit Care Med.* 1998; 26(11): 1801-6.
64. Ivy, M.E., et al. Abdominal compartment syndrome in patients with burns. *J Burn Care Rehabil.* 1999, 20(5): 351-3.
65. Latenser, B.A., et al. A pilot study comparing percutaneous decompression with decompressive laparotomy for acute abdominal compartment syndrome in thermal injury. *J Burn Care Rehabil.* 2002; 23(3): 190-5.
66. Hobson, K.G., et al. Release of abdominal compartment syndrome improves survival in patients with burn injury. *J Trauma.* 2002; 53(6): 1129-33.
67. Corcos, A.C, Sherman, H. Percutaneous treatment of secondary abdominal compartment syndrome. *J Trauma.* 2001; 51(6): 1062-4.