



Ciencia Rural

Universidade Federal de Santa Maria

cienciarural@mail.ufsm.br

ISSN (Versión impresa): 0103-8478

ISSN (Versión en línea): 1678-4596

BRASIL

2005

Juliana Regina Rossi / Silvana Martinez Baraldi-Artoni / Daniela Oliveira / Claudinei da  
Cruz / Vanessa Sobue Franzo / Alex Sagula

MORFOLOGIA DO BICO E DA LÍNGUA DE PERDIZES RHYNCHOTUS  
RUFESCENS

*Ciencia Rural*, setembro-outubro, año/vol. 35, número 005

Universidade Federal de Santa Maria

Santa Maria, Brasil

pp. 1098-1102



## Morphology of beak and tongue of partridge *Rhynchotus rufescens*<sup>1</sup>

### Morfologia do bico e da língua de perdizes *Rhynchotus rufescens*

Juliana Regina Rossi<sup>2</sup> Silvana Martinez Baraldi-Artoni<sup>3</sup> Daniela Oliveira<sup>4</sup>  
Claudinei da Cruz<sup>5</sup> Vanessa Sobue Franzo<sup>4</sup> Alex Sagula<sup>6</sup>

#### ABSTRACT

Twenty adult partridges *Rhynchotus rufescens* were used to study the morphology of the beak and the tongue. Lengths of the beak and of the tongue were evaluated, and histologic sections of the tongue were stained routinely with hematoxylin-eosin (HE), periodic acid-Schiff (PAS) and Masson's trichrome stain, later analyzed and described. The beak of the partridge of both sexes are curved, flat, hard and with a sharp extremity, with mean length of 4.90cm for the females and 4.80 for the males. The tongue is characterized by a triangular format with mean length of 1cm for both sexes, and its extremity is presented as a sharp format. Organization of the tongue tissue presents a stratified squamous epithelium with filiform papillae in all surface, mucous glands with ducts that project to the epithelium surface and a hyaline cartilage in the whole length of the tongue, which lays on the skeletal musculature that is guided in several directions.

**Key words:** beak, tongue, partridge, morphology.

#### RESUMO

Vinte perdizes *Rhynchotus rufescens* foram utilizadas para estudar a morfologia do bico e da língua. Os comprimentos do bico e da língua foram avaliados, e seções histológicas foram coradas com Hematoxilina-Eosina (HE), ácido periódico de Schiff (PAS) e tricromo de Masson, posteriormente analisadas e descritas. O bico da perdiz em ambos os sexos são curvos, duros e com uma extremidade pontiaguda tendo em média de 4,90cm de comprimento para as fêmeas e 4,80 para os machos. A língua é caracterizada por um formato triangular

e possui em média 1cm de comprimento para ambos os sexos, sendo sua extremidade pontiaguda. A organização histológica da língua apresenta epitélio estratificado queratinizado com papilas filiformes em toda a superfície, glândulas mucosas com ductos que se projetam na superfície epitelial e cartilagem hialina em todo o comprimento, localizada sobre a musculatura esquelética, a qual é orientada em várias direções.

**Palavras-chave:** bico, língua, perdiz, morfologia.

#### INTRODUCTION

Beak (modification of the lower and upper jaw), also denominated of ramphoteca, is a specialized structure responsible for the apprehension of the victuals. Psitaciidae use the beak for the locomotion; besides, it is used for defense, construction of the nest, brushing of the feathers and it is a source of bacterial infections installation, mycosis (candidiasis), parasitic (knemidoptiasis) and viruses. Several names are given to the different parts of the beaks of the birds. The sharp borders of both jaws can be: flat, indented or sawed according to the species (SISSON & GROSSMAN, 1986).

Rostral floor of chicken pharynx is mostly formed for the base or root of the tongue, which is

<sup>1</sup>Trabalho financiado pela Fundação de Apoio à Pesquisa do Estado de São Paulo (FAPESP).

<sup>2</sup>Programa de Pós-graduação em Genética e Melhoramento de Plantas, Faculdade de Ciências Agrárias e Veterinárias (FCAV), Universidade Estadual Paulista (UNESP), Jaboticabal, SP, Brasil.

<sup>3</sup>Departamento de Morfologia e Fisiologia Animal, FCAV, UNESP, Jaboticabal, SP, Brasil. E-mail: smbart@fcav.unesp.br. Autor para correspondência.

<sup>4</sup>FCAV, UNESP, Jaboticabal, SP, Brasil.

<sup>5</sup>Centro de Aquicultura da UNESP (CAUNESP), Jaboticabal, SP, Brasil.

<sup>6</sup>Curso de Biologia do Centro Universitário de Araraquara (UNIARA), Brasil.

fixed, being constituted by a mucosa and a stratified squamous epithelium (SISSON & GROSSMAN, 1986). GEORGE et al. (1998) related that this epithelium possesses a variable keratinization, and is continuous with the mucosa of the oral cavity. Dorsal face of the free part of the tongue is usually thicker; in the rostral region of the dorsal face there is a median furrow that is close to the radix. There are well-developed papillae, the papillae linguales (SISSON & GROSSMAN, 1986).

LINDENMAIER & KARE (1959) described a small number of structures, the taste buds, located in the epithelium of the tongue radix, caudally to the papillae. The taste organs are close to the salivary glands ducts and they resemble to the mammals ones. There are also rostral and caudal lingual salivary glands and the caudal ones are in the dorsal portion of the base of the tongue (HALPERN, 1962).

The purposes of this work were to describe morphologically the beak (anatomical study) and the tongue (anatomical and histological study) of the partridge *Rhynchotus rufescens*.

## MATERIAL AND METHODS

Twenty adult partridges *Rhynchotus rufescens* were used (10 males and 10 females). Tongue was collected and placed in a 10% formalin solution and lengths of the beak and of the tongue were evaluated.

For the histological study, fragments of the tongue were immersed in Bouin for 24 hours and later submitted to the dehydration process with alcohol and embedded in Paraplast (Merk®). Histologic sections of 7µm of thickness were obtained and they were stained routinely with hematoxylin-eosin (HE) and periodic acid-Schiff (PAS) (BEHMER et al., 1976). The sections were documented in Olympus microscope, model BX50, analyzed and described.

The anatomical nomenclature used was based on Nomina Anatomica Avium (NAA, BAUMELL et al., 1993) whenever possible.

After obtaining the data, variance analysis and qui-square test (5% significance) were calculated using the software "SAS" (1999) for comparison among the sexes.

## RESULTS AND DISCUSSION

Several parts of the digestive system, including the beak are considerably modified and adapted according to the diet birds receive (DYCE et al., 1996; BAILEY et al., 1997). The size of the beak seems to be an important factor in the regulation of

the ingestion. MACARI et al. (1994) showed that the birds have difficulty to consume particles that are larger or smaller than the anatomical dimension of the beak, and this would be an important factor that would influence the preference for the size of the particle. According to MACARI et al. (1994), the alimentary preference for particles of different sizes is influenced by the age of the chicken, and not for the chemical composition of the food. The selection of particles seems to be associated to the presence of sensorial organs and free terminations in the upper palate and in the beak (MACARI et al., 1994).

Analyzing the beak of the partridge, it was verified that for both sexes, they are curved, flat, hard and with a sharp extremity, with mean length of 4.90 cm for the females and 4.80 for the males (Table 1 and figure 1). The portions (dorsal and ventral) present a black and white collar, respectively (Figure 2A).

According to SICK (2001), *Rhynchotus* has a strong, long and curved beak because it digs the soil throwing it to the side, seeking and pulling tubercles and roots. It has preference for grasshoppers and peanut, which is swallowed with peel. Occasionally hunt small vertebrates as geckos, mice and even small snakes. They pick roots over all in the winter, when the insects are scarce.

The internal structure of the upper portion of the beak, in the caudal half of the palate, presents a longitudinal fissure in the medium line, characterized as choana, with absence of crests in the board of the fissure (Figure 2B).

In the floor of the oral cavity, the presence of the tongue is observed, and it is characterized by a triangular format with mean length of 1cm for both sexes (Table 1 and Figure 1), and its extremity is presented as a sharp format (Figure 2B), as observed in Otididae family by BAILEY et al. (1997). It is located in the caudal portion of the oral cavity and it has rosy coloration in the totality (Figure 2B). Its base has 0,7 cm of length, arrested by the frenule and for a free rostral part. The tongue presents a flat surface and the presence of papillae is not visualized macroscopically, contradicting the authors TURK

Table 1 - Mean values ± standard deviation and statistical analysis of beak and tongue lengths (cm) of females and males partridge *Rhynchotus rufescens*. Number of animals = 10.

	Beak	Tongue
Female	4,90 ± 0,84	0,99 ± 0,07
Male	4,80 ± 0,42	1,00 ± 0,00
F Value	0,11NS	0,18NS

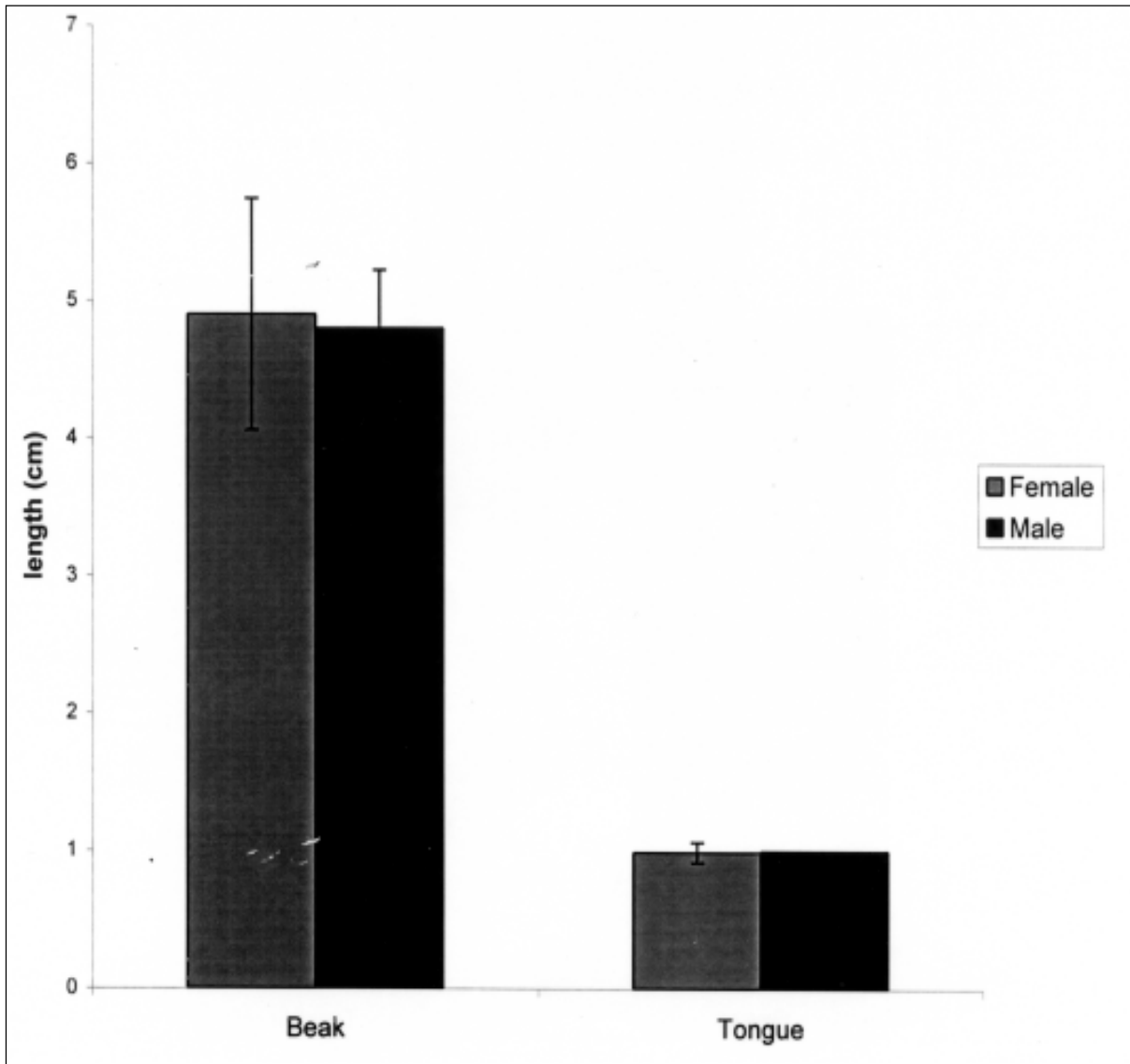


Figure 1 - Variation of mean values  $\pm$  standard deviation of beak and tongue lengths (cm) of females and males partridge *Rhynchotus rufescens*.

(1982) and BAILEY et al. (1997).

Histologically the partridge tongue presents a stratified squamous epithelium with filiform papillae in all surfaces. Papillae are thin projections of the epithelium, with no taste organs (mechanical papillae). Tongue humidity and thin papillae give a false flat appearance to the tongue macroscopic surface. The basal layer of the epithelium presents basal papillae (Figure 3A), which are projections of the stratified squamous epithelium in the adjacent connective tissue.

Below the epithelium, surrounded by connective tissue, there are mucous glands with ducts

that project to the epithelium surface (Figures 3B and 3C). Tongue skeleton is formed by a hyaline cartilage that crosses all its length and it fixes the skeletal muscles that are below the cartilage. It is ventrally of the connective tissue and lays on the skeletal musculature that is guided in several directions (Figure 3B and 3C). TUCKER (1966) described a bone in the tongue of the chicken that is united to a cartilage in the tongue apex, which is fixed to skeletal muscle.

Some mucous glands can be observed in the central and ventral areas of the tongue of partridge. Mucous glands are also found in the lateral border of the tongue. Caudal portion of the tongue communicates

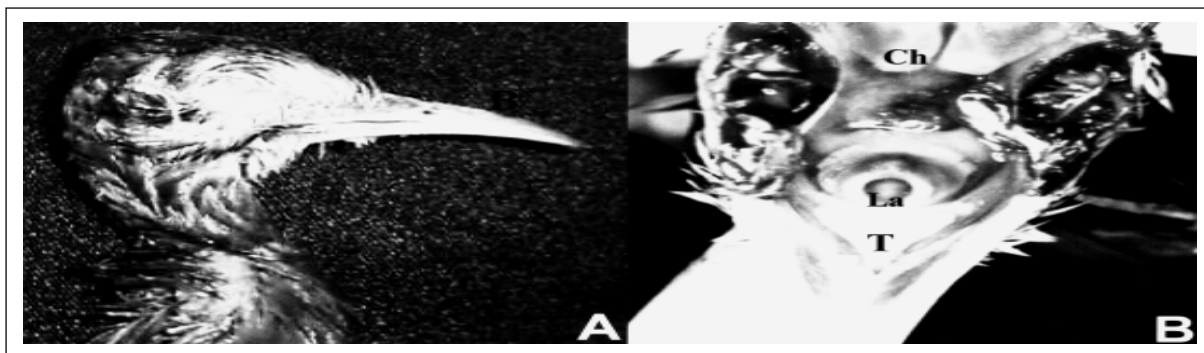


Figure 2 - A - Lateral view of the partridge head. Beak (B) comes long and curved. B - Interior of the partridge oral cavity. Tongue (T) is sharp, presents a triangular format and rosy coloration. Larynx (La), choana (Ch).

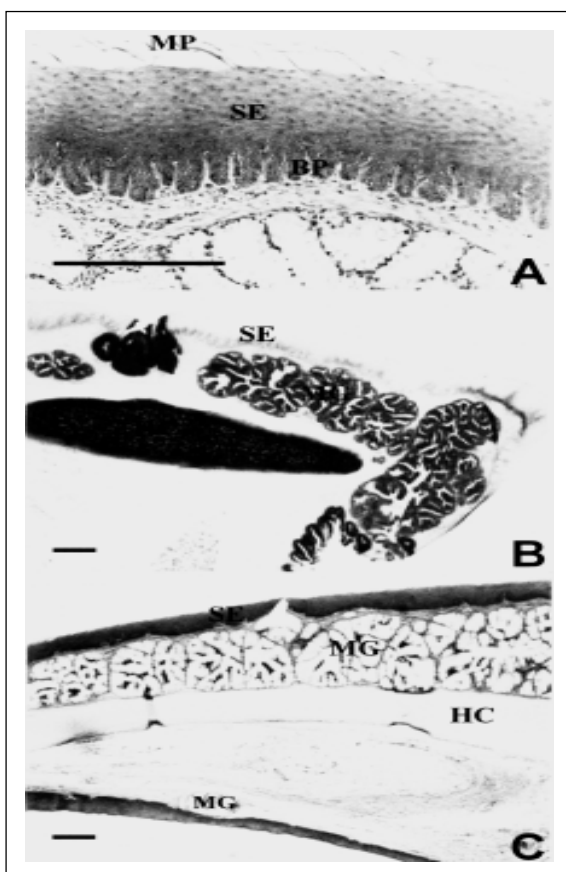


Figure 3 - A - Details of the mucosa of the partridge tongue. In the dorsal extremity it is noticed mechanical papillae (MP). Basal Papillae (BP). B - Transverse section of the partridge tongue. In the surface there is a squamous stratified epithelium (SE) and below, mucous glands (MG), laid on the hyaline cartilage (HC). PAS. C - Longitudinal section of the partridge tongue. Dorsal surface presents a squamous stratified epithelium (SE) and below there are mucous glands (MG) laid on the hyaline cartilage (HC). In the ventral surface a smaller number of mucous glands is observed. HE. Barr = 25µm.

with the oral cavity epithelium, presenting several mucous glands whose ducts open up in the partridge tongue surface (Figures 3B and 3C), as found by SISSON & GROSSMAN (1986), in chicken. It was not possible to describe taste buds with the stain technique used.

#### CONCLUSION

The beak of the partridge is curve and flattened and the tongue is triangular shaped with mechanical papillae, squamous stratified epithelium, mucous glands, hyaline cartilage and skeletal muscle in its constitution.

#### REFERENCES

- BAILEY, T.A. et al. Comparative morphology of the alimentary tract and its glandular derivatives of captive bustards. *Journal of Anatomy*. v.191, p.387-398, 1997.
- BAUMEL, J.J. et al. *Handbook of avian anatomy: nomina anatomica avium*. 2.ed. Cambridge : Nuttall Ornithological Club, 1993. 779p.
- BEHMER, O.A. et al. *Manual de técnicas para histologia normal e patológica*. São Paulo : Edart/Edusp, 1976. 240p.
- DYCE, K.M. et al. *Tratado de anatomia veterinária*. 2.ed. Rio de Janeiro : Guanabara Koogan, 1996. p.631-650.
- GEORGE, L.L. et al. *Histologia comparada*. 2.ed. São Paulo : Roca, 1998. 286p.
- HALPERN, B.P. Gustatory nerve responses in the chicken. *American Journal Physiology*, v.203, p.541-544, 1962.
- LINDENMAIER, P.; KARE, M.R. The taste end-organs of the chicken. *Poultry Science*, v.38, p.454-550, 1959.
- MACARI, M. et al. Anatomia e histologia funcional do trato digestivo. In: FUNDAÇÃO APINCO DE CIÊNCIA E TECNOLOGIA AVÍCOLAS. *Fisiologia da digestão e absorção das aves*. Campinas : APINCO, 1994. p.1-18.

“SAS”- STATISTICS ANALYSIS INSTITUTE. **Users guide**. North Caroline, 1999. 426p.

SICK, H. **Ornitologia brasileira**. 3.ed. Rio de Janeiro : Nova Fronteira, 2001. 912p.

SISSON, S.; GROSSMAN, J.D. **Anatomia dos animais domésticos**. 5.ed. Rio de Janeiro : Guanabara Koogan, 1986. 2000p.

TUKER, R. Differentiation of epithelial and connective tissue components in the tongue of *Gallus domesticus*. **Research of Veterinary Science**, v.7, p.1-16, 1966.

TURK, D.E. The anatomy of the avian digestive tract as related to feed utilization. **Poultry Science**. v.61, p.1225-1244, 1982.